

Investigation of dorsal/ventral skin and the parotoid region of *Lyciasalamandra billae* and *Lyciasalamandra luschani basoglui* (Urodela: Salamandridae)

Esra AKAT, Hüseyin ARIKAN & Bayram GÖÇMEN

Ege University, Science Faculty, Biology Department, Zoology Section, 35100 Bornova-Izmir, Turkey; esra.akat@ege.edu.tr

Abstract: In the present study, the parotoid region, dorsal and ventral integuments of *Lyciasalamandra billae* and *Lyciasalamandra luschani basoglui* were investigated in terms of localization of hyaluronic acid (HA) and histochemical characteristics. HA immunoreactivity was carried out using biotinylated hyaluronic acid binding protein (B-HABP) labelled with streptavidin-fluorescein isothiocyanate (FITC). HA was mainly localized in the stratum spongiosum of *L. billae* and *L. luschani basoglui* for water homeostasis and skin functionality. Light microscopic observations revealed that the dorsal and ventral integuments of *L. billae* and *L. luschani basoglui* exhibited basic morphological characteristics of other amphibians: the epidermis was composed of a stratified squamous epithelium and the dermis subdivided into stratum spongiosum and stratum compactum. Two different types of dermal glands (mucous and granular glands) were identified in the spongy dermis of the dorsal and ventral integuments whereas in the parotoid region, three different types of glands (mucous, granular and parotoid glands) were examined.

Key words: dermal glands; skin; hyaluronic acid; *Lyciasalamandra*

Introduction

Glycosaminoglycans (GAGs) are a major component of the extracellular matrix, glycocalyx, and synovial fluid. There are two main types of GAGs: non-sulphated GAGs (hyaluronic acid) and sulphated GAGs (chondroitin sulphate, dermatan sulphate, keratan sulphate, heparin and heparan sulphate). Hyaluronic acid (HA; syn. hyaluronan, hyaluronate) is unique among GAGs with respect to not being covalently bound to a polypeptide. It is synthesized in the plasma membrane of fibroblasts and other cells by addition of sugars to the reducing end of the polymer (Balazs et al. 1986; Laurent & Fraser 1992; Laurent et al. 1996; Kennett & Davies 2009). While HA was formerly known as a passive molecule, in recent years new roles of HA were demonstrated in active regulation of many biological processes, cell proliferation and migration. HA also causes leading modifications of the cell behavior and cell interaction in cancer and vascular diseases (Toole 1997; Göransson 2001; Toole et al. 2002; Turley et al. 2002).

The skin is an effective barrier between the inside and the outside of the organism and is one of the organism's crucial interfaces for contact and communication with its external environment (Proksch et al. 2008; Rakers et al. 2010). Due to the fact that amphibians inhabit a wide spectrum of habitats, the skin is a critical organ that performs several functions such as respiration, ion and water transport (Duellman & Trueb 1994; Stiffler

et al. 1997; Hoffman & Katz 1999; Sullivan et al. 2000). The amphibian skin, like that of any other vertebrate, comprises of epidermis and dermis (Fox 1986; Duellman & Trueb 1994), but it is characterized by having numerous dermal glands. According to structural, ultrastructural and histochemical properties, amphibians skin possesses two type of cutaneous glands which are mucous and serous (granular or venom) glands (Toledo & Jared 1995).

Although many salamander species have been described in the world, there are far fewer studies related to the integument morphology of salamander species, and there are no reports of skin morphology of *Lyciasalamandra*. This study was performed for the purpose of morphological and histochemical characterization, and demonstration of HA in *Lyciasalamandra billae* (Franzen et Klewen, 1987) and *Lyciasalamandra luschani basoglui* (Baran et Atatür, 1980) skin to provide a better understanding of the role of HA.

Material and methods

Animals

The present study was carried out according to the animal ethical committee of Ege University, Faculty of Medicine (permit no: 2011-091) and approved by Republic of Turkey Ministry of Forestry and Water Affairs (date: 11 April 2011, permit no: 42694). Four specimens (two adult males and two adult females) of *L. billae* and *L. luschani basoglui* were captured from Antalya (Turkey). The dorsum of *L. billae* is of salmon ground colour with some white spots dis-



Fig 1. A: Male *Lyciasalamandra billae*; B: Female *Lyciasalamandra luschani basoglui*.

tributed on the back and ordered regularly, forming two light dorsolateral bands. The parotoids are light yellow-salmon (Fig. 1A). The dorsal part of body in *L. luschani basoglui* is light yellowish-pink covered with randomly distributed brown spots of different sizes and brightness. The parotoids are lighter than the dorsal part of body. Both the extremities and tail are reddish with very small black spots (Fig. 1B). Sexual dimorphism for all *Lyciasalamandra* taxa is swollen cloacal region and hedonic protuberance above the tail base in males (Göçmen & Akman 2012).

Histochemistry

Animals were anaesthetized with ether, and euthanized by decapitation. Then skin samples from parotoid region in the both sides of the head and the anterior, middle and posterior back and belly region (16–25 mm² surface area) were obtained and immediately fixed in 4% paraformaldehyde overnight at 4°C. Thereafter, the tissue samples were rinsed with 0.1 M phosphate-buffered saline (PBS), pH 7.2, and processed according to the standard histological protocols for paraffin embedding. Five micrometer serial sections were stained with Gill's hematoxylin-eosin (HE) (modified Gill et al. 1974), Periodic acid-Schiff (PAS) (Lillie 1951), Alcian blue (AB) (Steedman 1950), Mallory's trichrome (Pantin 1946), Picro-Ponceau (Gurr 1956). After the stain with PAS and AB, counterstaining was carried out with HE.

Hyaluronic acid (HA) immunoreactivity was evaluated using biotinylated hyaluronic acid binding protein (B-HABP) (kindly obtained from Benaroya Research Institute). B-HABP was prepared from cartilage as described (Underhill et al. 1993). Sections were deparaffinized, and non-specific binding sites were blocked with 2% bovine serum albumin (BSA) in PBS, and then incubated in B-HABP labelled with FITC (streptavidin-fluorescein isothiocyanate) (Sigma Chemical Company). All washes were performed using PBS. Sections were evaluated and photographed using a Leica DM3000 microscope (Leica Microsystems) that was equipped with a Leica digital camera (DFC290). For negative control hyaluronidase digested sections were used. For positive control, sections were stained with B-HABP/HA.

Results

According to light microscopic observations, dorsal and ventral integuments of *Lyciasalamandra billae* and *L. luschani basoglui* were composed of epidermis and dermis. The epidermis in both *L. billae* and *L. luschani*

basoglui were composed of a stratified squamous epithelium and the epithelium exhibited weak keratinization (Figs 2A, C, D). The dermis consisted of a vascularized stratum spongiosum of loose connective tissue and the compact dermis was formed by mainly collagenous fibers that were compactly structured. Dermal glands were situated in the spongy dermis in both the dorsal and ventral regions (Figs 2A, E). Melanophores were situated in the dermis beneath the basement membrane of dorsal skin (Figs 2B, C) but they were not observed in the ventral region.

Two different types of dermal glands (mucous and granular glands) were identified in the dorsal and ventral regions. Mucous glands were more abundant than granular glands, and granular glands were rarely observed in both the dorsal and ventral sides of *L. billae* and *L. luschani basoglui*. In both specimens the percentage of serous glands in the dorsal region ranged from 10% to 15%, and in ventral region ranged from 3% to 6%. Mucous glands possessed an obvious lumen and were lined by mucocytes. These alveolar glands were filled with flocculent, amorphous secretory material. After the Periodic acid-Schiff (PAS) staining method, the content of mucous glands gave a positive reaction due to neutral mucosubstances. The content of mucous glands also reacted positively with AB for the presence of acid mucopolysaccharides (Figs 2B, E). Granular glands contained homogeneously distributed granules (Figs 2A, C), and the content of granular glands did not react with PAS and AB pH 2.5. The secretory contents of granular glands were shown to be acidophilic after Mallory's trichrome (Fig. 2C). Mucous and granular glands presented the same morphological and histochemical characteristics in both dorsal and ventral skin. After the Picro-Ponceau procedure collagenous fiber bundles were stained red (Fig. 2A).

In the parotoid region, three different types of glands (mucous, granular and parotoid glands) were examined. The parotoid region integument possessed small pores that connect with duct openings of parotoid glands. The parotoid glands consisted of an aggregation of secretory units and were larger than other glands (mucous and granular glands). These glands were surrounded by collagenous fiber bundles and were only lo-

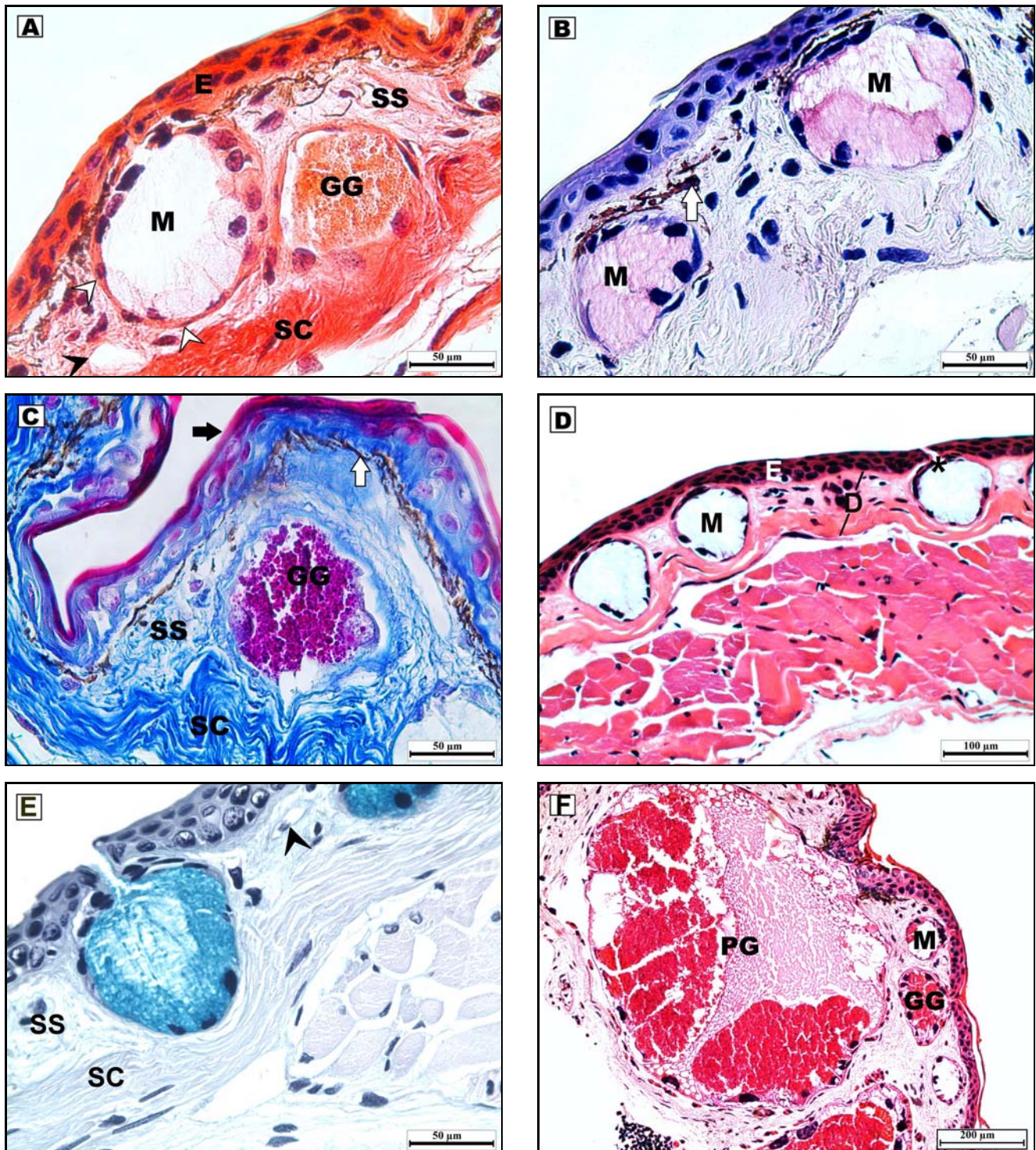


Fig. 2. A: Light microscopic view of dorsal skin of *L. billae*. The skin is formed by the epidermis and dermis. Dermal glands of located in stratum spongiosum, Picro-ponceau staining; B: Periodic acid-Schiff (PAS)+Hematoxylin positive reaction of mucous glands in *L. luschani basoglui* dorsal skin; C: The stratified squamous epithelium exhibited weak keratinization in the dorsal skin of *L. billae*, Mallory trichrome staining; D: Light microscopic view of ventral skin of *L. luschani basoglui*. Each gland was connected to the surface of the skin by epidermal duct, Hematoxylin-eosin (HE) staining; E: Flocculent, amorphous secretory material of mucous glands reacted with AB pH 2.5 in ventral integument of *L. luschani basoglui*; F: Parotoid region of *L. billae*, PAS+Hematoxylin, epidermis (E), dermis (D), stratum spongiosum (SS), stratum compactum (SC), mucous gland (M), granular gland (GG), parotoid gland (PG), melanophores (white arrow), keratinized cells (black arrow), blood vessel (black arrow head), myoepithelial cells (white arrow head), gland duct (*).

cated in the parotoid region. Therefore we preferred to use the term parotoid gland. Other dermal glands (mucous and granular glands) were observed to be beneath the epidermis in the parotoid region (Fig. 2F). All of dermal glands were enveloped by myoepithelial cells,

and each dermal gland was connected to the surface of the skin by an epidermal duct (Figs 2A, D, E).

HA immunoreactivity was evaluated using an FITC labelled specific probe (B-HABP) in paraffinized sections by fluorescent microscopy. This reaction oc-

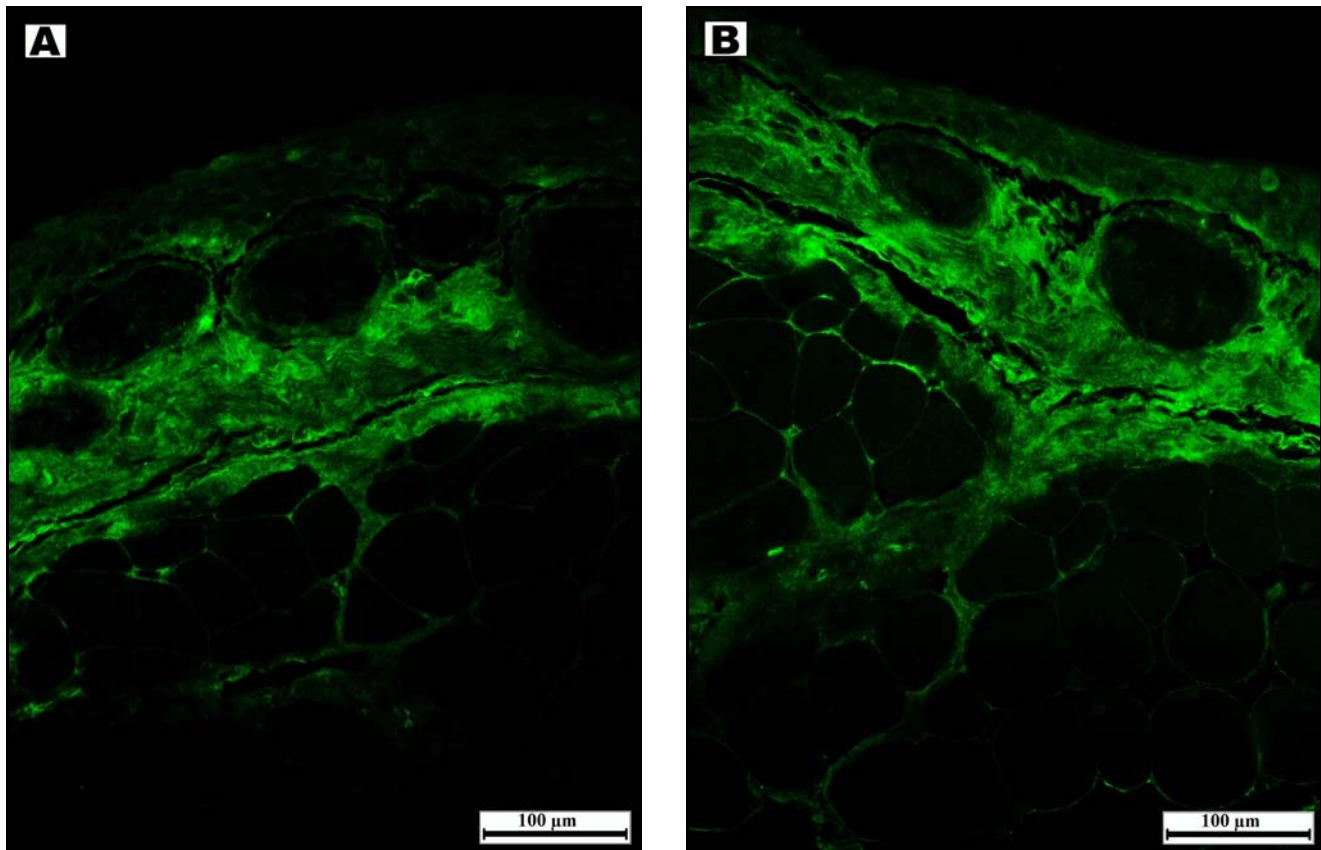


Fig. 3. Immunofluorescence localization of Hyaluronic acid (HA) in dermis of dorsal side. The localization of HA mainly in stratum spongiosum. A: Dorsal skin of *L. billae*; B: Dorsal skin of *L. luschani basoglui*.

curred with HA dispersed through the extracellular matrix. According to the HA immunoreactivity, it was localized in the dermis and was widely distributed in the stratum spongiosum around the mucous glands (Figs 3A, B).

Discussion

Amphibian skin is an important organ due to the fact that it performs critical functions as respiration, ion and water transportation, however, the morphological and functional complexities of this organ are not yet fully understood (Duellman & Trueb 1994; Stiffler et al. 1997; Hoffman & Katz 1999; Sullivan et al. 2000). In recent years, an increasing amount of work has been carried out about the morphology and structure of amphibian integument (de Brito-Gitirana & Azevedo 2005; Felseburgh et al. 2007, 2009; Gonçalves & de Brito-Gitirana 2008; Bingöl Ozakpınar & Murathanoglu 2011; Mangione et al. 2011). But, there are few reports related to morphology and structure of skin in salamander species.

In all the animals used in the present study, the epidermis was supported by the dermis which was composed of two layers which were stratum spongiosum and stratum compactum as described in other amphibians (Fox 1986; Duellman & Trueb 1994; Rigolo et al. 2008; Bingöl Ozakpınar & Murathanoglu 2011). The epidermis in both *L. billae* and *L. luschani basoglui* is com-

posed of a stratified squamous epithelium. The outer limit of epidermis is lined by keratinized cells and exhibits weak keratinization. In *Lithobates catesbeianus* (Shaw, 1802) (Pelli et al. 2010), the epidermis was constituted by a squamous epithelium lightly keratinized in contrast to the keratinized epidermis described for *Rhinella icterica* (Spix, 1824) (former *Bufo ictericus*) (de Brito-Gitirana & Azevedo 2005). The keratinization grade is related to animal adaptation to terrestrial environment, because keratins protect epithelial cells from mechanical stress (Gu & Coulombe 2007; Pelli et al. 2010).

Two types of dermal glands, mucous and granular glands in the stratum spongiosum of *L. billae* and *L. luschani basoglui* were observed. Wang et al. (2011) reported a relatively high degree of keratinization in the stratified epidermis and two kinds of glands, mucous and granular glands, in the salamander *Tylostotriton taliangensis* Liu, 1950. Gonçalves & de Brito-Gitirana (2008) determined two types of cutaneous glands; mucous and tubuloalveolar glands representing the main glandular type in *Cycloramphus fuliginosus* Tschudi, 1838. In *R. icterica*, two types of glands, mucous and venom, were detected by de Brito-Gitirana & Azevedo (2005). However, other authors (Warburg et al. 2000; Nosi et al. 2002) reported different types of dermal glands, such as lipid (wax) and mixed (seromucous gland). Bingöl Ozakpınar & Murathanoglu (2011) observed three types of skin glands; serous, mucous and

mixed glands in the dorsal and ventral parts of *Triturus karelinii* (Strauch, 1870). On the other hand, in the parotoid region of *L. billae* and *L. luschani basoglu*, three different types of glands (granular, mucous and parotoid glands) were identified. All types of glands were determined according to their morphology and standard histochemical staining reactions.

The HA immunoreactivity was localized in the dermis and widely distributed in the stratum spongiosum, around the mucous glands of *L. billae* and *L. luschani basoglu*. HA is a major component of connective tissue matrices, where it participates in promoting matrix assembly, viscosity of some fluids and tissue hydration because of its water binding property (Elkan 1968; Laurent et al. 1996). On the basis of these literatures, HA is conceivable as a water barrier, and it probably enables the transfer of water towards the epidermis and mucous glands in *L. billae* and *L. luschani basoglu*. Therefore, HA and mucus secretion of mucous glands work together to maintain skin moisture, enable the skin lubrication, and reduce mechanical friction.

HA is an important constituent of the interstitial barrier. It provides to decrease tissue permeability, thereby increasing the viscosity of tissue. Catalyzing the hydrolysis of hyaluronic acid by hyaluronidase causes increased tissue permeability. Therefore it is used in medicine in conjunction with other drugs to speed their dispersion and delivery. Some bacteria, such as *Staphylococcus aureus*, *Streptococcus pyogenes* and *Clostridium perfringens* produce hyaluronidase to hydrolysis of hyaluronic acid as means of increasing mobility through the body's tissues (Ponnuraj & Jedrzejas 2000; Lin & Stern 2001; Lokeshwar et al. 2002; Hajjaji et al. 2005; Kim et al. 2005; Girish & Kemparaju 2006; Necas et al. 2008). Based on these data, HA probably acts as a chemical and biological defence barrier. Therefore, HA is widely localized in the stratum spongiosum beneath the epidermis of *L. billae* and *L. luschani basoglu*.

Consequently, this study revealed morphological and histochemical characteristics of dorsal/ventral skin and the parotoid region of *L. billae* and *L. luschani basoglu*. For immunohistochemistry, HA probably acts a significant role in water balance and as a chemical and biological defence barrier.

Acknowledgements

The authors thank Paul Bollyky to supply B-HABP and his invaluable help about immunohistochemistry. Thanks also to Yücel Akgül for his valuable advices related to immunohistochemistry.

References

- Balazs E.A., Laurent T.C. & Jeanloz R.W. 1986. Nomenclature of hyaluronic acid. *Biochem. J.* **235** (3): 903.
- Bingol Ozakpinar O. & Murathanoglu O. 2011. The morphology of the dorsal and ventral skin of *Triturus karelinii* (Caudata: Salamandridae). *Biologia* **66** (2): 349–356. DOI: 10.2478/s11756-011-0009-2
- de Brito-Gitirana L. & Azevedo R.A. 2005. Morphology of *Bufo ictericus* integument (Amphibia, Bufonidae). *Micron* **36** (6): 532–538. DOI: 10.1016/j.micron.2005.03.013
- Duellman W.E. & Trueb L. 1994. *Biology of Amphibians*. 2nd edn. Johns Hopkins University Ltd, London, 670 pp. ISBN: 080184780X, 9780801847806
- Elkan E. 1968. Mucopolysaccharides in the anuran defense against desiccation. *J. Zool.* **155** (1): 19–53. DOI: 10.1111/j.1469-7998.1968.tb03028.x
- Felseburgh F.A., Almeida P.G., Carvalho-e-Silva S.P. & de Brito-Gitirana L. 2009. Microscopical methods promote the understanding of the integument biology of *Rhinella ornata*. *Micron* **40** (2): 198–205. DOI: 10.1016/j.micron.2008.09.003
- Felseburgh F.A., Carvalho-e-Silva S.P. & de Brito-Gitirana L. 2007. Morphological characterization of the anuran integument of the *Proceratophrys* and *Odontophrynus* genera (Amphibia, Anura, Leptodactylidae). *Micron* **38** (5): 439–445. DOI: 10.1016/j.micron.2006.06.015
- Fox H. 1986. The skin of Amphibia. *Epidermis*, pp. 78–149. In: Bereiter-Hahn J., Matoltsy A.G. & Richards S. (eds), *Biology of the Integument Vol. 2. Vertebrates*, Springer, Berlin, 855 pp. ISBN-10: 3540132449, ISBN-13: 978-3540132448
- Gill G.W., Frost J.K. & Miller K.A. 1974. A new formula for a halfoxidized hematoxylin solution that neither overstains nor requires differentiation. *Acta Cytol.* **18** (4): 300–311. PMID: 4135333
- Girish K.S. & Kemparaju K. 2006. Inhibition of *Naja naja* venom hyaluronidase: Role in the management of poisonous bite. *Life Sci.* **78** (13): 1433–1440. DOI: 10.1016/j.lfs.2005.07.015
- Gonçalves V.F. & de Brito-Gitirana L. 2008. Structure of the sexually dimorphic gland of *Cycloramphus fuliginosus* (Amphibia, Anura, Cycloramphidae). *Micron* **39** (1): 32–39. DOI: 10.1016/j.micron.2007.08.005
- Göçmen B. & Akman B. 2012. *Lyciasalamandra arikani* n. sp. & *L. yehudahi* n. sp. (Amphibia: Salamandridae), two new Lycian salamanders from Southwestern Anatolia. *North-West J. Zool.* **8** (1): 181–194.
- Göransson V. 2001. *Hyaluronan and Renal Fluid Handling. Studies during Normal and Pathological Conditions of Renal Function*. Acta Universitatis Upsaliensis, Comprehensive, Summaries of Uppsala Dissertations from the Faculty of Medicine 1090, Uppsala, 62 pp. ISBN: 91-554-5146-2
- Gu Li-H. & Coulombe P.A. 2007. Keratin function in skin epithelia: a broadening palette with surprising shades. *Curr. Opin. Cell Biol.* **19** (1): 13–23. DOI: 10.1016/j.ccb.2006.12.007
- Gurr E. 1956. *A Practical Manual of Medical and Biological Staining Techniques*. 2nd edn. Interscience Publishers, Inc., New York, 451 pp.
- Hajjaji H.E., Cole A.A. & Manicourt D.H. 2005. Chondrocytes, synoviocytes and dermal fibroblasts all express PH-20, a hyaluronidase active at neutral pH. *Arthritis Res. Ther.* **7**: R756–R768. DOI: 10.1186/ar1730
- Hoffman J. & Katz U. 1999. Elevated plasma osmotic concentration stimulates water absorption response in a toad. *J. Exp. Zool.* **284** (2): 168–173. DOI: 10.1002/(SICI)1097-010X(19990701)284:23.3.CO;2-F
- Kennett E.C. & Davies M.J. 2009. Glycosaminoglycans are fragmented by hydroxyl, carbonate, and nitrogen dioxide radicals in a site-selective manner: implications for peroxynitrite-mediated damage at sites of inflammation. *Free Radical Biol. Med.* **47** (4): 389–400. DOI: 10.1016/j.freeradbiomed.2009.05.002
- Kim E., Baba D., Kimura M., Yamashita M., Kashiwabara S. & Baba T. 2005. Identification of a hyaluronidase, Hyal5, involved in penetration of mouse sperm through cumulus mass. *Proc. Nat. Acad. Sci. USA* **102** (50): 18028–18033. DOI: 10.1073/pnas.0506825102
- Laurent T.C. & Fraser J.R.E. 1992. Hyaluronan. *FASEB J.* **6** (7): 2397–2404.
- Laurent T.C., Laurent U.B.G. & Fraser J.R.E. 1996. The structure and function of hyaluronan: An overview. *Immunol. Cell Biol.* **74**: A1–A7. DOI: 10.1038/ichb.1996.32
- Lillie R.D. 1951. The allochrome procedure; a differential method segregating the connective tissues collagen, reticulum and

- basement membranes into two groups. *Am. J. Clin. Pathol.* **21** (5): 484–488. PMID: 14829424
- Lin G. & Stern R. 2001. Plasma hyaluronidase (Hyal-1) promotes tumor cell cycling. *Cancer Lett.* **163** (1): 95–101. DOI: 10.1016/S0304-3835(00)00669-8
- Lokeshwar V.B., Schroeder G.L., Carey R.I., Soloway M.S. & Iida N. 2002. Regulation of hyaluronidase activity by alternative mRNA splicing. *J. Biol. Chem.* **277** (37): 33654–33663. DOI: 10.1074/jbc.M203821200
- Mangione S., Garcia G. & Cardozo O.M. 2011. The Eberth-Katschenko layer in three species of ceratophryines anurans (Anura: Ceratophryidae). *Acta Zool. (Stockholm)* **92** (1): 21–26. DOI: 10.1111/j.1463-6395.2009.00442.x
- Necas J., Bartosikova L., Brauner P. & Kolar J. 2008. Hyaluronic acid (hyaluronan): a review. *Vet. Med. Czech.* **53** (8): 397–411.
- Nosi D., Terreni A., Alvarez B.B. & Delfino G. 2002. Serous gland polymorphism in the skin of *Phyllomedusa hypochondrialis azurea* (Anura: Hylidae): Response by different gland types to norepinephrine stimulation. *Zoomorphology* **121** (3): 139–148. DOI: 10.1007/s004350100051
- Pantin C.F.A. 1946. Notes on Microscopical Technique for Zoologists. Cambridge University Press, Cambridge, 75 pp.
- Pelli A.A., Cinelli L.P., Mourão P.A.S. & de Brito-Gitirana L. 2010. Glycosaminoglycans and glycoconjugates in the adult anuran integument (*Lithobates catesbeianus*). *Micron* **41** (6): 660–665. DOI: 10.1016/j.micron.2010.03.001
- Ponnuraj K. & Jedrzejewski M. 2000. Mechanism of hyaluronan binding and degradation: Structure of *Streptococcus pneumoniae* hyaluronate lyase in complex with hyaluronic acid disaccharide at 1.7 Å resolution. *J. Mol. Biol.* **299** (4): 885–895. DOI: 10.1006/jmbi.2000.3817
- Proksch E., Brandner J.M. & Jensen J.M. 2008. The skin: an indispensable barrier. *Exp. Dermatol.* **17** (12): 1063–1072. DOI: 10.1111/j.1600-0625.2008.00786.x
- Rakers S., Gebert M., Uppalapati S., Meyer W., Maderson P., Sell A.F., Kruse C. & Paus R. 2010. 'Fish matters': the relevance of fish skin biology to investigative dermatology. *Exp. Dermatol.* **19** (4): 313–324. DOI: 10.1111/j.1600-0625.2009.01059.x
- Rigolo J.R., Almeida J.A. & Ananias F. 2008. Histochemistry of skin glands of *Trachycephalus* aff. *venulosus* Laurenti, 1768 (Anura, Hylidae). *Micron* **39** (1): 56–60. DOI: 10.1016/j.micron.2007.08.006
- Steedman H.F. 1950. Alcian blue 8G: a new stain for mucin. *Q. J. Microsc. Sci.* **91**: 477–479.
- Stiffler D.F., Eskandari S. & Dejbakhsh S. 1997. Cutaneous transport of Ca²⁺ in the frog *Rana pipiens*: significance and specificity. *J. Exp. Zool.* **277** (5): 371–381. DOI: 10.1002/(SICI)1097-010X(19970401)277:5<371::AID-JEZ3>3.0.CO;2-M
- Sullivan P.A., Hoff K.S. & Hillyard S.D. 2000. Effects of anion substitution on hydration behavior and water uptake of the red-spotted toad, *Bufo punctatus*: is there an anion paradox in amphibian skin? *Chem. Senses* **25** (2): 167–172. PMID: 10781023
- Toledo R.C. & Jared C. 1995. Cutaneous granular glands and amphibian venoms. *Comp. Biochem. Physiol.* **111A** (1): 1–29. DOI: 10.1016/0300-9629(95)98515-1
- Toole B.P. 1997. Hyaluronan in morphogenesis. *J. Intern. Med.* **242** (1): 35–40. PMID: 9260564
- Toole B.P., Wight T.N. & Tammi M.I. 2002. Hyaluronan-cell interaction in cancer vascular disease. *J. Biol. Chem.* **277**: 4593–4596. DOI: 10.1074/jbc.R100039200
- Turley E.A., Noble P.W. & Bourguignon L.Y. 2002. Signaling properties of hyaluronan receptors. *J. Biol. Chem.* **277**: 4589–4592. DOI: 10.1074/jbc.R100038200
- Underhill C.B., Nguyen H.A., Shizari M. & Culty M. 1993. CD44 positive macrophages take up hyaluronan during lung development. *Dev. Biol.* **155** (2): 324–336. DOI: 10.1006/dbio.1993.1032
- Wang N., Liu S. & Zeng L. 2011. Histological observation on skin of *Tylototriton taliangensis*. *Sichuan J. Zool.* **30** (1): 66–68.
- Warburg M.R., Rosenberg M., Roberts J.R. & Heatwole H. 2000. Cutaneous glands in the Australian hylid *Litoria caerulea* (Amphibia, Hylidae). *Anat. Histol. Embryol.* **201** (5): 341–348. PMID: 10839630

Received August 26, 2013
Accepted November 16, 2013